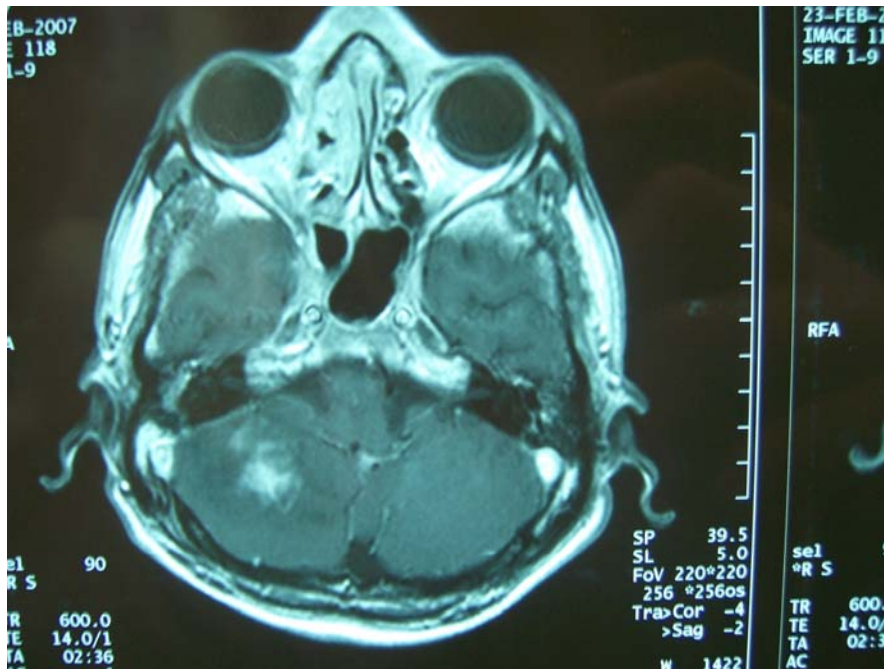


GORGAS CANADIAN PATIENT CARE FUND 2011

Illustrative patients who benefited
from the fund

Free living amoebiasis by *Balamuthia mandrillaris*

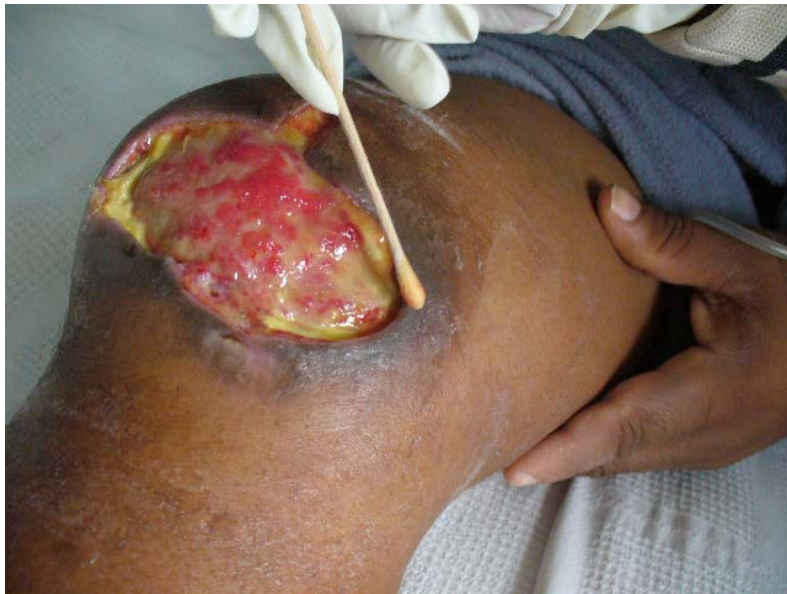

Patient from Ica

Received support in:

1. Diagnosis: brain MRI
2. Treatment : albendazol

Buruli ulcer: *Mycobacterium ulcerans*

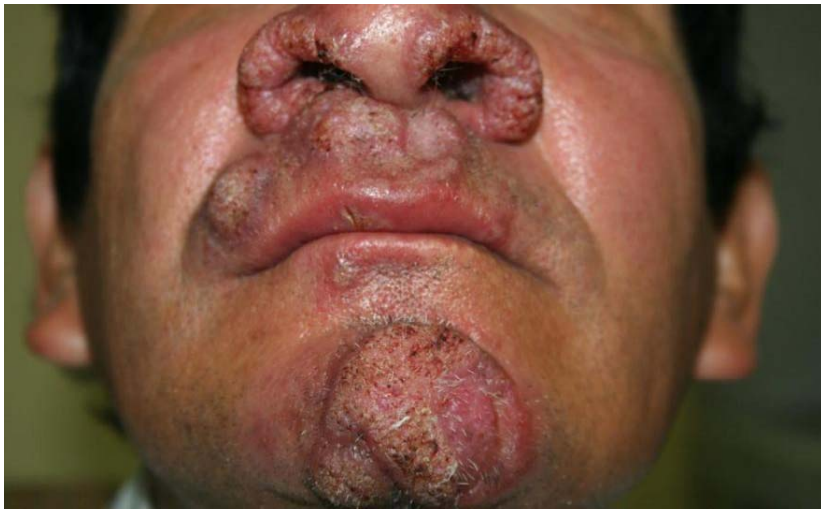


Patient from Tumbes

Received support in:

1. Diagnosis; Ziehl-Neelsen stains, and culture
1. Images to rule-out deeper extension
2. Treatment: rifampicin+amikacin
3. Accommodation in Lima

Mucosal leishmaniasis

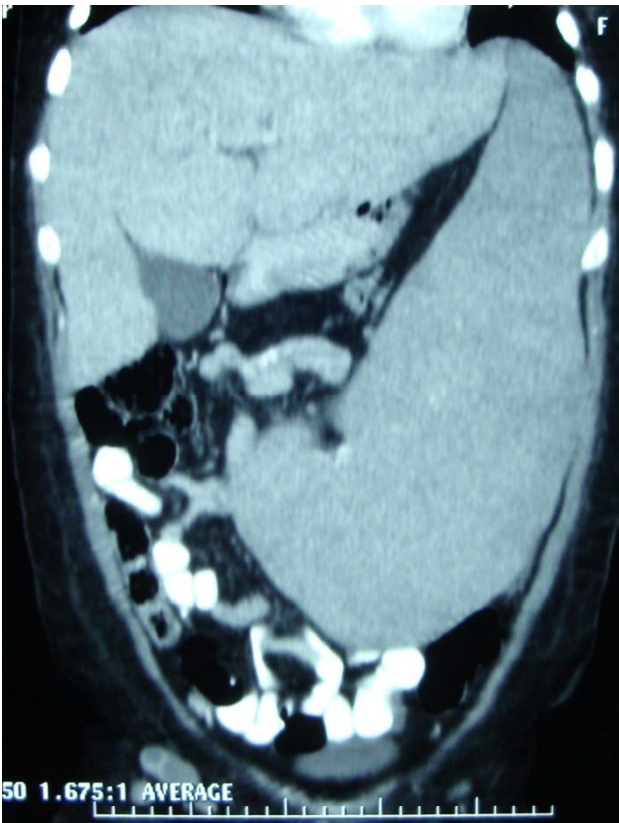

Patient from the jungle of
Madre de Dios

Received support in:

1. Diagnosis: biopsy-culture
2. Follow-up

Juvenile Paracoccidioidomycosis

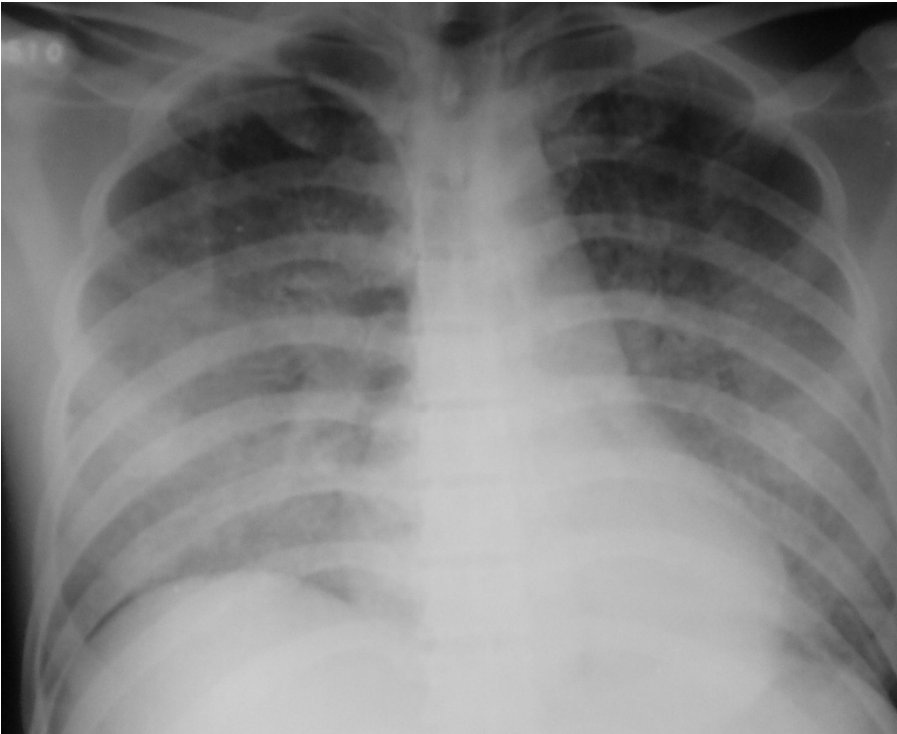

Patient from the jungle of Pucallpa

Received support in:

1. Diagnosis: cultures
2. Imaging: chest and abdominal CT scans
3. Treatment: itraconazol
4. Follow-up

Disseminated histoplasmosis in an HIV-infected patient

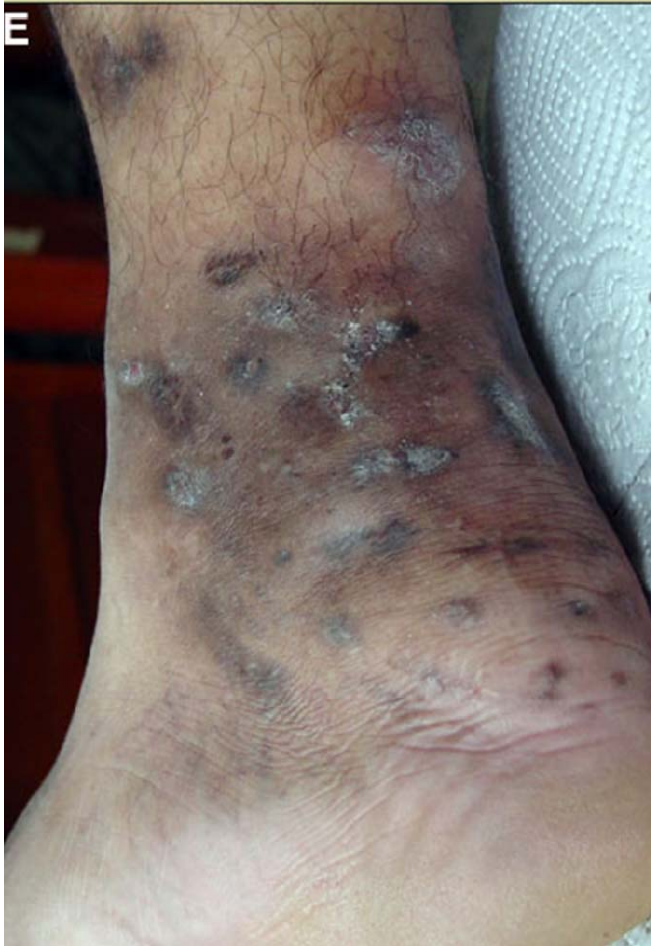

Patient from the jungle of Tarapoto

Received support in:

1. Diagnosis: bone marrow culture
2. Treatment with itraconazol
3. Follow-up

Fungal mycetoma



Patient from the South of Lima

Received support in:

1. Diagnosis
2. Treatment with itraconazol
3. Follow-up